

Pancreatic Cancer

Pancreatic Cancer: Pathology

Some Pre-Cancerous Lesions

Pancreatic Intraepithelial Neoplasia (PanIN)

Mucinous Cystic Neoplasm (MCN)

Intraductal Papillary Mucinous Neoplasm (IPMN)
risk of transformation to invasive cancer 25%

Invasive Intraepithelial Neoplasm

> 85% Ductal Adenocarcinoma

Other: acinar cell, neuroendocrine

Pancreatic Cancer: Risk Factors

Clinical Risk Factors

Risk Factors

- Age (avg 70)
- Smoking
- ETOH
- Obesity
- DM
- Pancreatitis

Screening

if 1st degree family hx or genetic syndrome

EUS or MRI/MRCP

Genetic Risk Factors

BRCA

Homologous recombination DNA repair
BRCA2 > BRCA1

PALB2

Localizer of BRCA

Lynch Syndrome/Hereditary Nonpolyposis Colorectal Cancer (HNPCC)

Syndrome = Colon, endometrial, uroepithelial, pancreatic, CNS, etc
MLH1, MSH2/6, PMS2 → dMMR → MSI-H

Other

- ATM
- CHEK
- TP53
- STK11 (Peutz Jegher)
- SMAD4

Pancreatic Cancer: Diagnosis & Staging

Work Up

Imaging

Triphasic CT
MRI/MRCP
EUS/ERCP

* Most tumors occur at head of pancreas

Tumor Markers

CA19-9
* can be falsely elevated w/ hyperbilirubinemia

CEA, CA-125

Staging

T

T1 = < 2 cm

T2 = > 2 cm

T3 = extra-pancreatic

T4 = involves celiac axis/SMA

Stage

Stage III = T4 or 4+ LN

Stage IV = M+

Prognosis

10-20% have resectable disease at diagnosis

For resected disease > 80% recur

Localized: 5Y OS 40%

Stage IV: 5Y OS 3%

Pancreatic Cancer: Resectability

Resectable 20%

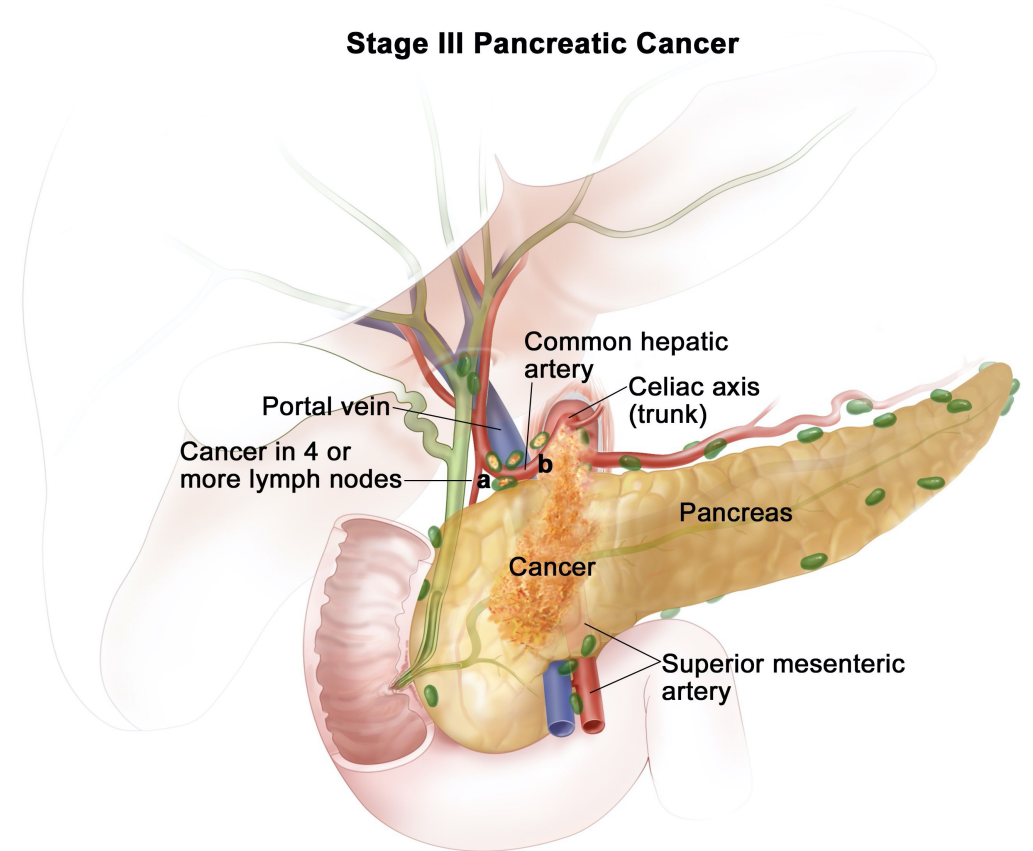
No significant involvement of SMA/vasculature
Surgery + Adjuvant Chemo

Borderline Resectable 40%

< 180° involvement of SMA/Celiac
Neoadjuvant Chemo +/- RT + Surgery + Adjuvant Chemo

Unresectable 40%

> 180° involvement of SMA/Celiac
Distant metastases (liver, peritoneum, etc)
Chemo



© 2018 Terese Winslow LLC
U.S. Govt. has certain rights

American Cancer Society

Pancreatic Cancer: Surgery for Early Stage Disease

Indications for Surgery

Resectable

No significant involvement of SMA/cealic

Surgery + Adj. Chemo

Borderline Resectable

< 180° involvement of SMA/cealic

Neo. Chemo +/- RT + Surgery + Adj. Chemo

* Also consider neoadjuvant therapy if: elevated CA 19-9 after relief of any obstruction, extreme weight loss, abdominal pain, large tumor or regional LNs

Head of Pancreas

→ **Pancreaticoduodenectomy = "Whipple"**
anterior pancreas
duodenum
gallbladder

Body/Tail of Pancreas

→ **Distal Pancreatectomy + Splenectomy**
distal pancreas
spleen

Adjuvant Chemo

6-12 weeks after surgery

Pancreatic Cancer: Adjuvant Chemo for Early Stage Disease

Adjuvant Chemotherapy

Resectable

No significant involvement of vasculature

Surgery + Adj. Chemo

Borderline Resectable

< 180° involvement of SMA/ceiac

Neo. Chemo +/- RT + Surgery + Adj. Chemo

Adjuvant Chemotherapy

FOLFIRINOX (FOL) 5FU/Leucovorin
* preferred (IRIN) Irinotecan
(OX) Oxaliplatin

Gemcitabine +/- Abraxane
Gemcitabine +/- Capecitabine
* gentler regimens

Notable Side Effects:

5FU → Hand-foot Syndrome (PPE), stomatitis, diarrhea, angina, mild alopecia, NASH

Irinotecan → Watery secretory diarrhea, mild alopecia, NASH

Oxaliplatin → Neuropathy, nephropathy, ototoxicity, cold hypersensitivity

Gemcitabine → Edema, rash, transaminitis/hyperbilirubinemia

Abraxane → Neuropathy, EKG changes, edema, rash

Pancreatic Cancer: Metastatic Disease Treatment

Front Line Chemo Regimens

FOLFIRINOX

* preferred

(FOL) 5FU/Leucovorin

(IRIN) Irinotecan

(OX) Oxaliplatin

Can drop oxaliplatin after 4-6 months

Gemcitabine +/- Abraxane

Gemcitabine +/- Erlotinib

* gentler regimen

LFTs: Irinotecan and gemcitabine both require hepatic dose adjustments

Second Line:

No FOLFIRINOX in second-line setting

can use FOLFOX, FOLFIRI

No Gemcitabine therapy if used front-line

Special Populations:

BRCA/PALB/ATM/CHEK Mutations

Platinum-based chemotherapy (ex: Gemcitabine/Cisplatin)

PARP inhibitors (Olaparib)

dMMR/MSI-High

Pembrolizumab

Notable Side Effects:

5FU → Hand-foot Syndrome (PPE), stomatitis, diarrhea, angina, alopecia, NASH

Irinotecan → Watery secretory diarrhea, alopecia, NASH

Oxaliplatin → Neuropathy, nephropathy, ototoxicity, cold hypersensitivity

Gemcitabine → Edema, rash, transaminitis/hyperbilirubinemia

Abraxane → Neuropathy, EKG changes, edema, rash

Pembrolizumab → Dermatitis, Hepatitis, Thyroiditis, ANY "itis"

Pancreatic Cancer Reference Handout

Pancreatic Cancer Dx & Staging

Invasive Intraepithelial Neoplasm

> 85% Ductal Adenocarcinoma
Other: acinar cell, neuroendocrine

Work Up

Imaging

Triphasic CT
MRI/MRCP
EUS/ERCP

Tumor Markers

CA19-9 (can be falsely elevated)
CEA, CA-125

Staging

T

T1 = < 2 cm
T2 = > 2 cm
T3 = extra-pancreatic
T4 = involves celiac axis/SMA

Stage

Stage III = T4 or 4+ LN
Stage IV = M+

Resectable 20%

No significant contact with SMA/cealic
Surgery + Adjuvant Chemo

Borderline Resectable 40%

< 180° involvement of SMA/cealic
Neo. ChemoRT + Surgery + Adj. Chemo

Unresectable 40%

> 180° involvement of SMA/cealic
Distant metastases
Chemo

Tx Early Pancreatic Cancer

Surgery

Head of Pancreas → Pancreaticoduodenectomy = "Whipple"
Body/Tail of Pancreas → Distal Pancreatectomy

Adjuvant Chemo 6-12 weeks after surgery

Adjuvant Chemotherapy

FOLFIRINOX (FOL) 5FU/Leucovorin
* preferred (IRIN) Irinotecan
(OX) Oxaliplatin

Gemcitabine +/- Abraxane or +/- Capecitabine

Tx Metastatic Pancreatic Cancer

Front Line Chemo Regimens

FOLFIRINOX (FOL) 5FU/Leucovorin
* preferred (IRIN) Irinotecan
(OX) Oxaliplatin

Gemcitabine +/- Abraxane
Gemcitabine +/- Erlotinib
* gentler

Second Line:

No FOLFIRINOX in second-line setting
No Gemcitabine therapy if used front-line

Special Populations:

BRCA/PALB/ATM/CHEK Mutations

Platinum-based chemotherapy (ex: Gem/Cis)
PARP inhibitors (Olaparib)

dMMR/MSI-High

Pembrolizumab

Notable Side Effects:

5FU → Hand-foot Syndrome (PPE), stomatitis, diarrhea, angina, alopecia, NASH
Irinotecan → Watery secretory diarrhea, alopecia, NASH
Oxaliplatin → Neuropathy, nephropathy, ototoxicity, cold hypersensitivity
Gemcitabine → Edema, rash, transaminitis/hyperbilirubinemia
Abraxane → Neuropathy, EKG changes, edema, rash
Pembrolizumab → Dermatitis, Hepatitis, Thyroiditis, ANY "itis"